

Detection of Tumor in Mammogram Images using Extended Local Minima Threshold

P. Natarajan ^{#1}, Debsmita Ghosh ^{#2}, Kenkre Natasha Sandeep ^{#2}, Sabiha Jilani ^{#2}

^{#1} Assistant Professor (Senior), School of Computing Science and Engineering, VIT University, Vellore, India

^{#2} B.Tech student, School of Computing Science and Engineering, VIT University, Vellore, India

¹ pnatarajan@vit.ac.in

² debsmita07@gmail.com

² nats_scorp14@yahoo.co.in

² jilani.sabiha162@gmail.com

Abstract— The field of medical imaging is gaining importance with an increase in the demand for automated, reliable, fast and efficient diagnosis. Breast cancer accounts for 22.9% of illnesses amongst women worldwide. Identification plays an important part in the diagnosis of benign and malignant tumors. A prime reason behind an increase in the number of cancer patients worldwide is the ignorance towards treatment of a tumor in its early stages. This project is initiated with basic pre-processing steps using filtering, contrast adjustment and stretching techniques. These techniques aid in noise removal, thus obtaining a well-defined tumor to work upon. In order to clearly demarcate the tumor from the rest of the original image, several methods have been applied, which include image subtraction and extending the minima function of the image. This is then followed by filling in holes near the tumor and applying segmentation techniques to the image. Therefore, the final image displays the tumor, encircled within a border, against the original image.

Keyword- Breast, Contrast Adjust, Tumor Detection, Extended Minima, Mammogram, Top-hat Filter

I. INTRODUCTION

Breast tumors are uncontrolled and abnormal proliferations of cells. Some originate in the breast itself, in which case they are termed primary. Others spread to this location from somewhere else in the body through metastasis, and are termed as secondary. Primary breast tumors do not spread to other body sites, and can be malignant or benign. Secondary breast tumors are always malignant. Both types are potentially disabling and life threatening. Tumors in the breast originally start developing from the breast tissue itself. It is far more common in women than in men. Breast cancer accounts for 22.9% of illnesses amongst women worldwide. Its survival rates are much lower in developing nations. The reason why there is focus upon breast tumors is because many women ignore the presence of lumps in their breasts. This lump later turns cancerous and tends to be more deadly.

Medical Image analysis and processing has great significance in the field of medicine, especially in non-invasive treatment and clinical study. Medical imaging techniques and analysis tools enable both doctors and radiologists to arrive at a specific diagnosis. Medical Image Processing has emerged as one of the most important tools to identify as well as diagnose various disorders. Imaging helps the doctors to visualize and analyze the image for understanding of abnormalities in internal structures. Mammograms detect signals emitted from normal and abnormal tissue, providing clear images of most tumors. It has become a widely-used method of high quality medical imaging, used widely in breast imaging, where soft tissue contrast and non-invasiveness are clear advantages.

II. RELATED WORKS

Many algorithms have been developed for detection of tumors in mammograms. The ones presented below are amongst the most notable.

A. Calcification Detection using Segmentation Method

The method proposed initially categorizes the inputted mammogram as probable calcification areas [5]. Owing to the textured background of the mammogram, minute blobs are identified by employing appropriate local thresholding [1] [3] and region growing [1] [3] procedure. Pattern recognition [1] [3] techniques help in reducing the quantity of pseudo blobs procured in the previous step.

B. Density Slicing

The original image is preprocessed by smoothing using Gaussian filters and sub-sampling techniques[1], following which intensity links are set up into the neighbouring regions from the central parts of the masses,

therefore, aiding in segmentation of the mass regions[7].

C. Multiresolution Analysis with a Bayesian Classifier

The system sets a threshold, which is chosen depending on the image inputted, to segment the tumors from its background. This is performed by employing a multiscale analysis of the image probability density function.

D. Mamdani Inference Systems

The model consists of two detection systems for masses and microcalcifications in mammogram images [8]. Using the four features provided by the Mamdani inference system, the identification of microcalcifications is performed. The four features are B- descriptor, D- descriptor, the mean intensity within the boundary, and the difference in the intensities between the inner and outer regions of the boundary. The detection of masses is done using features like central intensity, mean intensity and maxmin average intensity.

E. Density Weighted Contrast Enhancement Filter

An Adaptive Density Weighted Contrast Enhancement (DWCE) filter in concurrence with Laplacian-Gaussian (LG) edge detection enhances facets of the mammogram images such that an edge detection algorithm can be applied in order to delineate the peripheral limits of the masses [6]. After acquiring the margins of the masses, morphological features are then inferred from them. These features are then fed to a classification algorithm, which helps to make a distinction between the various areas of the image.

F. Pattern Matching

The method contains two seminal parts. The first part aims to segment the breast by removal of the background and its labels. The second part involves establishing the regions of the masses present in the mammogram images. The given system maps a typical mass area to the mammogram image, which helps to pinpoint and separating the suspicious part from the tested image [10].

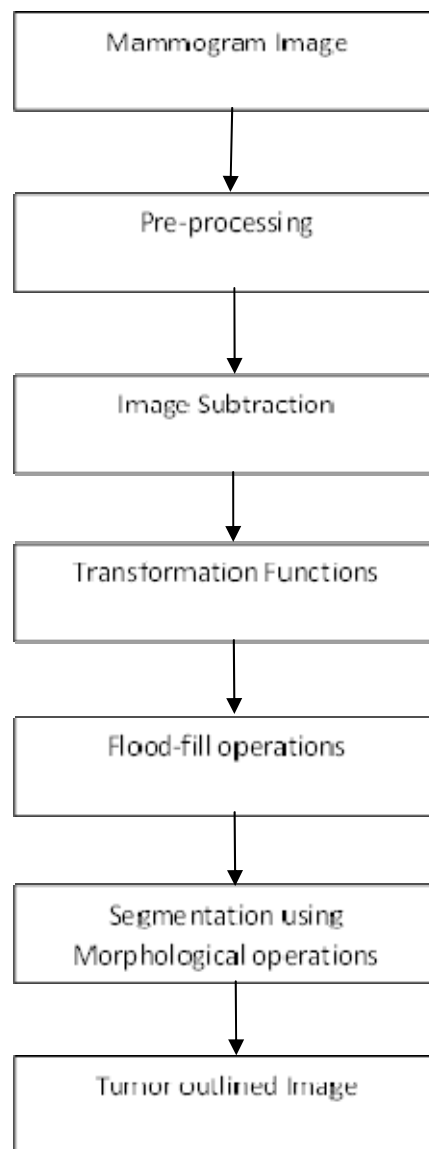
III. DESCRIPTION

The aim of the project is tumor identification in mammogram images. The main reason for detection of mammogram tumors is to provide aid to clinical diagnosis. Mammogram tumor classification is a leading area of research. The aim is to provide an algorithm that guarantees the presence of a tumor by combining several procedures to provide a foolproof method of tumor detection in a mammogram. The methods utilized are filtering, contrast saturation, stretching of an image, image subtraction, inversion, filling, segmentation and outlining of the tumor.

The objective of the project is detection of a breast tumor by analysis of its mammogram. A tumor is an abnormal growth of cells in the human body. In this paper, the focus is entirely upon breast tumors. Tumors can be classified as either benign, which is non-cancerous, or malignant, which is cancerous. Benign tumors generally have well-rounded edges, are almost perfectly circular and do not have the tendency to spread. On the other hand, malignant tumors are irregularly shaped and tend to spread to other parts of the breast. By utilizing the algorithm proposed in this paper, the objective is to successfully identify the presence of a tumor in the breast.

The use of computer technology in medical decision support is now widespread and pervasive across a wide range of medical area such as cancer research, gastroenterology, brain tumors etc. Mammography is the viable option now for the study of tumors in breasts. The method clearly finds tumor, size and location. Mammography builds up a picture and has no known side effects related to radiation exposure. It displays much higher details in soft tissues. Researcher had proposed various features for identifying tumors in mammograms.

IV. ARCHITECTURE



V. METHODOLOGY

A. Filtering

As a grayscale or coloured image maybe the inputted image, the first step is to convert the given image into a grayscale image. On procuring the grayscale image, the aim then is to filter it. In the algorithm, top-hat filtering [2] is applied. It is first applied by using the strel [4] function on the grayscale image. After application of the strel image, the top hat filter is applied.

B. Contrast Adjustment

In order to provide a clear and well-defined image to work upon, two operations are further applied to the top hat filtered image. The first operation involves increasing the contrast of the filtered image, which is accomplished by performing contrast adjustment techniques. Furthermore, the second operation involves stretching the contrast adjusted image [2]. The output of these two operations on the top hat filtered image provides an image which is more consistent, containing few irregularities and having concise borders.

C. Image Subtraction

The next series of operations employed by us is a subtraction operation [4]. The first subtraction operation subtracts the stretched image from the grayscale image. The next subtraction operation subtracts the output of the previous subtracted image from the stretched image. The output of the first subtraction operation, when

subtracted from the output of the second operation gives the final subtracted image. The sole purpose of subtraction of images is to minimize the faint inconsistencies in the image to the greatest extent possible.

D. Extended Minima Threshold

Working with the final subtracted image, a function is applied to it in order to extend the minima [3]. On obtaining the extended minima output, the next step in the algorithm is the inversion of the extended minima function. By applying the inversion function, the black and white regions of the image are inverted with respect to the extended minima image [4]. In the inverted image, the tumor along with minute spots remains in white, whereas the remaining image is black. Thus, the tumor is highlighted, but with minor irregularities. Therefore, the next step is to focus upon removing these irregularities.

E. Removal of Irregularities

Employing a certain function enables the removal of minor irregularities surrounding the tumor by filling them [1] [4]. Furthermore, using the filled image as a base, the outline of the breast in the mammogram is removed to intensify the tumor in the mammogram.

F. Segmentation and Display of Outlined Image

One of the last steps in the algorithm is segmentation [3]. Segmentation is performed using a combination of strel and erode [4] operations. Completion of the segmentation technique provides an easy interface upon, which the tumor is easily displayed by means of an outline [2] [5] [10]. Thus, in the final output image of the algorithm, the tumor will have a clear and well-defined outline around it. In case the input does not contain any tumor at all, then the final output image will have a faint outline, which won't encircle any specific part at all.

G. Area Calculation of Tumor

Upon successful delineation of the tumor, its area is calculated [4]. The algorithm presented in this paper has been tested on very many images. Area calculation of a tumor aids medical professionals to accurately determine the possible size of the tumor. Furthermore, the algorithm provides the approximate location of the tumor as well. As a result, medical diagnosis is considerably accelerated and the treatment is then continued, depending upon the type of tumor and advice of medical practitioner.

VI. RESULTS AND DISCUSSION

This paper focuses upon the detection of a tumor in the breast from mammogram images. By utilizing various image processing techniques such as filtering [2], contrast adjustment, image stretching, image subtraction, transformation operations, flood fill operations [1][4] and segmentation, the demarcation of the tumor in the mammogram image is obtained. The following results showcase the outputs received after each step in the algorithm.

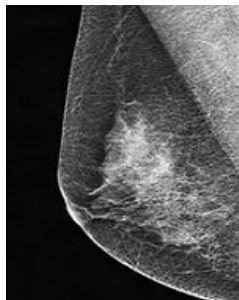

Fig. 1. Original Image

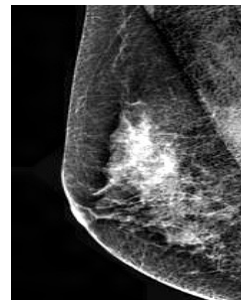


Fig. 2. Pre-processed Image

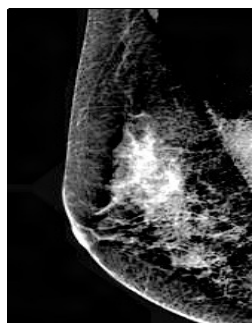


Fig. 3. Subtracted Image



Fig. 4. Transformed Image



Fig. 5. Flood-filled Image

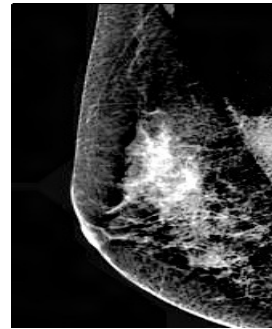


Fig. 6. Segmented Image

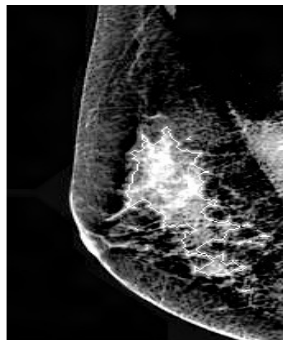
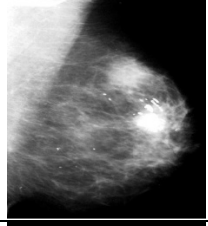

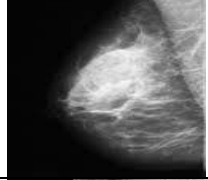
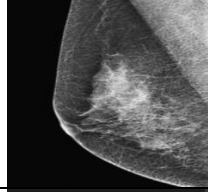



Fig. 7. Final Image

VII. CONCLUSION

The proposed algorithm is inputted with gray scale images as well as RGB mammogram images that contain tumor/s. This mammogram image is processed through various stages. The RGB image has first been converted to gray scale image and then Top-Hat filtering has been used. Various operations such as contrast adjustment have been applied in order to adjust the contrast of the filtered image, contrast stretching is used to obtain stretched image. Various subtraction functions were also applied in order to obtain a final subtracted image. Extension of the minima regions in the final subtracted image have been procured, following which the obtained image is inverted in order to get the inverted extended image. The holes in the image have been filled to reduce the irregularities surrounding the tumor. Moreover, the border of the image containing the tumor is cleared and the tumor is segmented and extracted using morphological operations. Hence, the tumor is outlined in the original image and clearly demarcated. The following table exhibits the size, mean and Peak Signal to Noise Ratio (PSNR) of mammogram images tested using the algorithm.

TABLE I
Properties of tested mammogram images

IMAGE	SIZE	MEAN	PSNR
	3.9785e+004	Mean1=91.6502 Mean2=15.1178	7.3294
	2.6044e+004	Mean1=28.4170 Mean2=33.1801	20.9579
	7.3579e+003	Mean1=73.9217 Mean2=41.8404	13.6310
	2.5934e+004	Mean1=71.9601 Mean2=45.4841	12.4749
	6.4239e+003	Mean1=59.1638 Mean2=21.0756	14.3373

REFERENCES

- [1] W.Gonzalez, "Digital Image Processing", 2nd ed. Prentice Hall, Year of Publication 2008.
- [2] Y.Ireaneus Anna Rejani, Dr.S.ThamaraiSelvi, "Early detection of breast cancer using svm classifier technique", International Journal on Computer Science and Engineering Vol.1(3), 2009, 127-130
- [3] Rafael C. Gonzalez, Richard E. Woods, Digital Image Processing, Second Edition.
- [4] Rafael C. Gonzalez, Richard E. Woods, Steve L. Eddins, Digital Image Processing Using MATLAB, 2003.
- [5] S. A. Hojjatoleslami, J. Kittler, "Automatic Detection of calcification in mammograms", Image Processing And Its Applications, 4-6 July 1995 Conference Publication No. 410, IEEE 1995.
- [6] Nicholas Petrick, Heang-Ping Chan, BerkmanSahiner, Datong Wei," An Adaptive Density-Weighted Contrast Enhancement Filter for Mammographic Breast Mass Detection",IEEE TRANSACTIONS ON MEDICAL IMAGING, VOL. 15, NO. 1, FEBRUARY 1996.
- [7] Naga R. Mudigonda, Rangaraj M. Rangayyan, J. E. Leo Desautels,"Detection of Breast Masses in Mammograms by Density Slicing and Texture Flow-Field Analysis", IEEE TRANSACTIONS ON MEDICAL IMAGING, VOL. 20, NO. 12, DECEMBER 2001.
- [8] Sansanee Auephanwiriyaikul, Siripen Attrapadung, Sutasinee Thovutikul, and Nipon Theera-Umpon,"Breast Abnormality Detection in Mammograms Using Fuzzy Inference System", The 2005 IEEE International Conference on Fuzzy Systems, 0-7803-9158-6.
- [9] XinshengZhang,HuaXie,"A New Approach for Clustered Microcalcifications Detection", 2009 Asia-Pacific Conference on Information Processing, 978-0-7695-3699-6.
- [10] Mohamed MeselhyEltoukh, Ibrahima Faye, BrahimBelhaouariSamir, "Automatic Detection of Breast Masses in Digital Mammograms Using Pattern Matching", 2010 IEEE EMBS Conference on Biomedical Engineering & Sciences (IECBES 2010), Kuala Lumpur, Malaysia, 30th November - 2nd December 2010.